

Herpes zoster of face Treated with Homoeopathic Medicine Hepar Sulph : A case Report

Dr Kanchan. R. Tayade * (Corresponding author)

MD (Homoeopathy)

Professor & HOD, Department of Pathology, Dr. D.Y. Patil Homoeopathic Medical College & R.C., Dr. D.Y. Patil Vidyapeeth, Pune, Maharashtra, India.

Address – Flat no 7, Ganesh 4 Apartment, near Ashwini Hospital Bijali nagar Chinchwad Pune 411033.

Abstract :

Introduction: Reactivation of the varicella-zoster virus causes the viral illness known as herpes zoster, or shingles. The varicella-zoster virus stays dormant in the neurological system following a bout of varicella (chicken pox).

classically characterized by erythematous papules that start out tightly spaced and quickly grow into vesicles on an oedematous and erythematous base. Lesions may manifest unilaterally in one, two, or more adjacent dermatomes as continuous or interrupted bands.

Conventional treatments are antiviral therapy, antibiotics, creams, and analgesics. Alternative medicine, especially homeopathy, is the second choice of therapy, as per the WHO. Case reports of herpes zoster of the face in the medical literature are scant. We aim to report a case treated with homoeopathic constitutional medicine in a young girl suffering from herpes zoster. Case Summary: A 16-year-old girl presented with the symptoms of a vesicular erythematous rash on her face with voluptuous itching and pain. With weakness and pain in the eyes for 2 days. A local examination suggested a herpes

zoster of the face. Individualized homoeopathic medicine hepar Sulph was prescribed in centesimal potency, which showed a positive role in the treatment of herpes zoster. Modified Naranjo criteria were used to illustrate the causal attribution of changes in her condition to the homoeopathic therapy. Future observational studies and randomized control trials would be conducted to determine the effectiveness of homeopathy in treating Herpes zoster patients.

Keywords: *Hepar Suph*, Homoeopathy, Individualised medicine, low of similar , herpes zoster

Introduction-

The varicella zoster virus, which carries the latent reactivation feature and causes chicken pox in childhood, is the source of herpes zoster infection[1]. Herpes zoster is an infection that affects cranial or peripheral nerves and is brought on by the varicella-zoster virus reactivating. greater risk if you are older than 60 or have impaired immune function.

emerges as painful skin eruptions that cover one dermatome, two neighboring dermatomes, or more, and stay inside the midline. The diagnosis is usually made without the need for laboratory testing, based only on the patient's history and physical examination of a characteristic clinical appearance. Herpes can be diagnosed with certainty via direct fluorescent antibody detection, polymerase chain reaction, and viral culture.

When antiviral medication is applied within 72 hours of the onset of a cutaneous lesion, it can speed up healing, diminish the severity of viral damage, shorten the duration of pain, and lower the risk of complications.

Complications: postherpetic neuralgia, bacterial superinfection, aseptic meningitis, and involvement of the viscera. Its clinical course varies, and in order to avoid problems, quick medical attention is needed. Homoeopathy, as a medical method, provides an efficient treatment by lessening the infection's symptoms and subsequent spread.

A CASE REPORT OF herpes and case series demonstrated the effectiveness of homoeopathic constitutional Similimum in the management of herpes zoster.[]

Case Report Patient Information A 16-year-old girl came to the Outpatient Department of Dr. D.Y. Patil Homoeopathic Medical College and Research Centre on August 9, 2023, with complaints of voluptuous itching on the rash of the face, constant pain in that area of the face, weakness, feverish feeling, and lassitude for 1 week. Initially, the patient had taken antiviral medicine, applied cream locally, and taken a few doses of acetaminophen for pain and fever herself, which provided temporary relief. She was lean, thin, and had a whitish complexion. She had a history of hepatitis C and chicken pox during her childhood and an episode of pain in the abdomen with a loss of appetite a year ago, which was treated with allopathic treatment. The patient was studying in 10th grade. Family history was insignificant.

Generals The patient was obstinate and irritable. Her memory and intellect were good, but due to weakness, she was not able to concentrate on studies. She was sleepy and longed for company. The appetite decreased with the desire for chicken, bread, coffee, and ice cream. She was thirstless, with dryness of mouth. The patient also had a tendency to profusely sweat only on the head, which was not offensive in nature and did not stain the clothes. Her bowel movement was regular, and the character of her stool was hard and non-offensive. Typically, the patient preferred to lie down following a small amount of physical activity and sound sleep.

. She was aggravated by the sun's heat and warmth, and her thermal reaction was hot. Her menses were regular, leucorrhoea before menses and pain in the lower abdomen.

Clinical findings Clinical findings were vesicular rash on the face, reddish in appearance, and small vesicles around the eyes. A rash on the right side of the face suggested herpes zoster of the face. [Figure 1] The temperature was 98.8 °F. The case fulfilled the clinical

diagnosis of herpes zoster of the face as per the Centers for Disease Control and Prevention 2015. [7] Repertorial analysis Repertorization was done by Zomo Homeopathic Software (Mind Technologies, Mumbai, Maharashtra, India), which prioritizes mental generals over physical generals, followed by specific symptoms. [Figure 2]. After the repertorial analysis, Hepar Sulph was found to cover 07 out of 07 rubrics and scored the highest marks, i.e., 12. Silicea scored the same 12 but covered only 4 rubrics, and both Ant Tart and Merc Sol covered the rubrics (04) and scored 11 marks. After consulting Homoeopathic Materia Medica, Hepar Sulph was prescribed. The indications for prescription were a lean, thin patient with weakness and sleepiness, being irritable and angry easily, sweating head on, herpetic eruption on face and cheeks, itching in herpetic eruption, herpetic eruption around orbit, desire for spicy food, thirstlessness, and a chilly thermal reaction. Prescription Two doses of Hepar sulph 200c were prescribed on the day of the first visit, along with a placebo for 1 week. The patient was advised to take rest and increase nutritious foods in her diet. The patient was followed for another 6 months, and no complication or relapse of the symptoms was noted during this period [Table 1].

Figure 1: patients' eruption on face before treatment picture on 9th August 2023

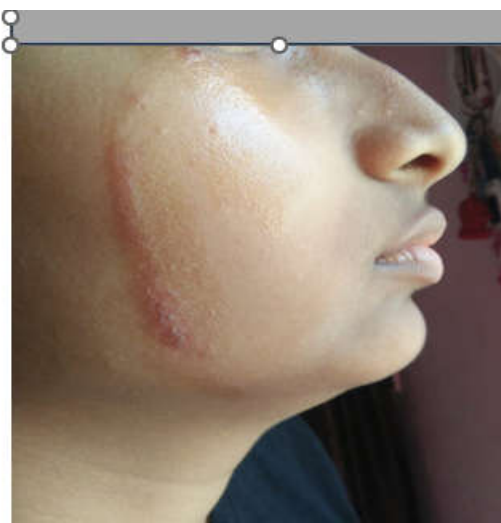

Figure 2: patients' eruption on face after treatment picture on 16th August 2023




Figure 2: Repertorisation chart

| Symptoms: 7 Remedies: 408 | | Show Repertorisation Tools | | | | | | | | | | Prescribe | Remedy List | Record | Replace |
|--|--|----------------------------|-----|-------|------|------|-----|-----|-------|-------|--|-----------|-------------|--------|---------|
| Remedy Name | | Hep | Sil | Ant-t | Merc | Puls | Lyc | Ars | Sulph | Staph | | | | | |
| Totals | | 12 | 12 | 11 | 11 | 11 | 10 | 10 | 10 | 9 | | | | | |
| Symptoms Covered | | 7 | 4 | 4 | 4 | 4 | 4 | 3 | 3 | 4 | | | | | |
| Kingdom | | | | | | | | | | | | | | | |
| [Murphy] [Face]Herpes, face:Cheeks: (25) | | 1 | 1 | 1 | 1 | | | | | 1 | | | | | |
| [Murphy] [Eyes]Herpes, about the eyes:Orbits, around: (2) | | 1 | | | | | | | | | | | | | |
| [Knerr] [Fever]Sweat:Head, on: (25) | | 3 | 4 | 3 | 4 | 4 | 3 | | | | | | | | |
| [Gentry] [Mind and disposition]Irritable:Peevish, angry, easily offended: (7) | | 1 | | | | | | | | | | | | | |
| [Complete] [Stomach]Thirstlessness: (366) | | 3 | 3 | 4 | 3 | 4 | 4 | 4 | 4 | 3 | | | | | |
| [Complete] [Skin]Eruptions:Herpetic:Itching: (86) | | 1 | 4 | 3 | 3 | 1 | 2 | 4 | 3 | 4 | | | | | |
| [Murphy] [Food]Spicy, general, (see Condiments, Highly seasoned):Desire... | | 2 | | | | 2 | 1 | 2 | 3 | 1 | | | | | |

Table 1: follow up -

| Date of follow-up | Main complaints | Prescription |
|-------------------|---|---|
| 9 August 2023 | voluptuous itching on the region of face with vesicular eruption on | Hepar Sulph 200 4 pills stat dose given. Placebo 4 pills BD for 3 days |

| | | |
|------------------|--|-------------------------------|
| | right side of face small vesical around orbit right side only. Sleepy feeling, thirstless. | |
| 12 august 2023 | Pain itching decreases, appetite improved. | Placebo for 5 days |
| 16 august 2023 | No pain and itching, healing seen. generals are improved. sleepy feeling is disappeared. | Placebo continue for 15 days. |
| 1 September 2023 | No other complaint | Placebo continue |

The patient was followed for another 6 months, and no complication or relapse of the symptoms was noted during this period

Discussion

Typically, herpes zoster can be identified with ease based on the clinical presentation of characteristic lesions in a dermatomal distribution.

Herpes zoster is generally diagnosed on the basis of its distinct appearance. It manifested as unilateral, painful, vesicular rashes following a dermatome. Conventional treatment includes analgesics and antiviral medicines. Herpes zoster is a latent viral infection that is

generally related to immune status, and post-herpetic neuralgia remains for many months and is not cured after treatment. The main aim is to prevent complications. A medical system called homeopathy focuses on treating the patient rather than the illness. It also seeks to restore health in a quick, gentle, and long-lasting manner. [10] The patient already had a history of chicken pox at the age of 13 and was treated allopathically. She had applied ointment to the skin, and for pain she was taking analgesics for weakness, pain, and itching intermittently for 1 week. She had taken medicines. After beginning homoeopathic treatment, she was receiving only homoeopathic care.

Her itching pain decreases without ointment; the skin is improving, and her generals are also improving. No recurrence was noted for 6 months after stopping the homeopathic treatment. Here, with the help of single constitutional medicine in a minimum dose, the patient got relieved. One medication, Hepar Sulph, is administered according to totality, with as little dosage repeated as necessary based on patient need. This case report describes the effectiveness of constitutional homoeopathic treatment in a case of herpes. The remedy was selected on the basis of repertorization together with consulting homoeopathic Materia Medica. A marked improvement in the symptoms were noted gradually in subsequent visits and marked

resolution after the complete course of treatment, which showed the positive role of constitutional medicine in the treatment of herpes in a young girl. When used as directed, appropriate anti-miasmatic and constitutional medications have been shown to be beneficial in the treatment of several illnesses. The Organon of Medicine's guidelines must be strictly followed when choosing potency, dosage, and repetition.

Conclusion

The present case report evidently suggests the successful treatment of herpes and restoration of the well-being of the patient with the help of constitutional homoeopathic medicine. Within 10 days of treatment, the patient was cured. This case has highlighted the importance of a holistic approach in the treatment considering the individuality of a patient for remedy selection, and not just disease symptoms. However, it would not be appropriate to generalize the usefulness of homeopathy. in cases of herpes on the basis of this single case report. Therefore, to determine the outcome reported in this case study, randomized control trials with observational controls are recommended.

Consent Written consent is obtained from parents for images and other clinical information to be reported in the journal, and written consent is available upon request. Efforts will be made to conceal the identity of the patient

Financial support and sponsorship Nil.

Conflicts of interest- None declared.

References

1. Roberts F., Macduff E. Textbook of Pathology Illustrated. 8th ed. Elsevier publication, London, New York.; 2018.pg.no. 120,595.
2. Braunwald E., fauci A.,Kasper D., hauser S., Longo D., Jameson J.L, Textbook of Harrison's principles of internal medicine, 15th ed. Vol -1, international edition ,Mcgraw-Hill Medical Publisher ,New York.;2001. pg.no.1106-1111.
3. Haslett C, Chilvers ER, Boon NA, Hunter J., Textbook Of Davison's Principles and Practice of Medicine. 18th ed. Churchill Livingstone Publishers London New York .; 2000. p. 1012.
4. Van Haselen RA. Homeopathic clinical case reports: Development of a supplement (HOM-CASE) to the CARE clinical case reporting guideline. Complement Ther Med 2016;25:78-85

5. Shah J. ZOMEIO - Homoeopathic Software By Homeopath. Mumbai: Mind Technologies Pvt. Ltd.; 2002.
6. Hahnemann S. Organon of Medicine. 6th ed. Translated by Dudgeon RE. William Boericke 26th Impression. New Delhi: B. Jain; 2010.
7. Suraia Parveen, Ahmed Z, Das S., Homoeopathic Treatment of Childhood Herpes Zoster—A Case Series, Homoeopathic Links 2023; 36(02): 137-146
DOI: 10.1055/s-0042-1756494
8. Gupta Y., Pande k. Evidence-Based Homoeopathic Treatment of Acute Herpes Zoster (Shingles): A Case Report, Homoeopathic Links 2021; Vol. 34 issue (04): pg. no. 307-310
DOI: 10.1055/s-0041-1736227
9. Boericke W., Pocket Manual of Homoeopathic Materia Medica with Repertory. Ninth edition. Kolkata. Rup Publications 2014.
10. Clarke J.H. A Dictionary of Practical Materia Medica, Vol.I, London. The Homoeopathic Publishing Company, 1900, Page no.
11. A Manual of Materia Medica, Therapeutics and Pharmacology with Clinical Index A.L. Blackwood, 10th impression, published by B. Jain Publishers 2016,
12. Burt WM.H., Physiological Materia Medica, 3rd Ed., B. Jain Publisher PVT ;2019.
13. Hahnemann S. Organon of Medicine by R.E.Dudgeon, 5th and 6th ed combined. New Delhi. Indian Book & Periodicals Publishers; 2007